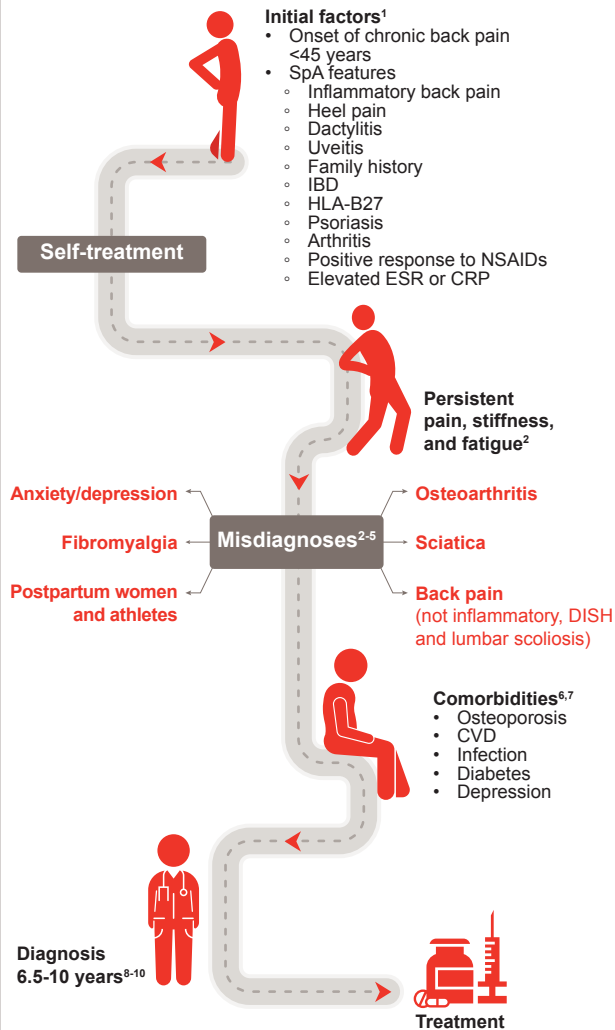
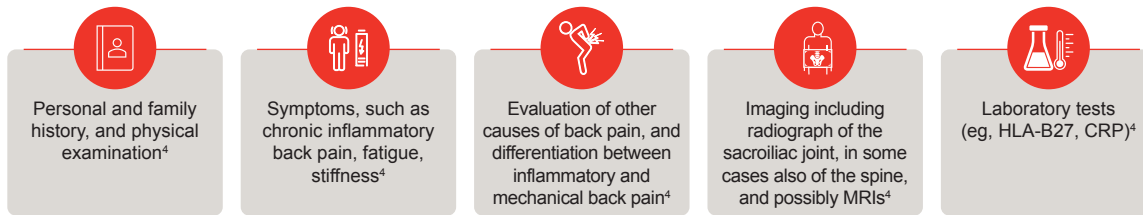


# Journey to an axSpA Diagnosis – Recognizing the Complex Clinical Picture

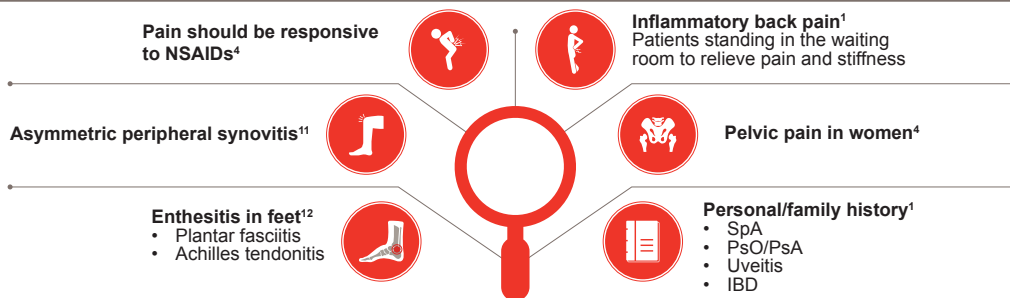
Average time to diagnosis is 6 - 10 years



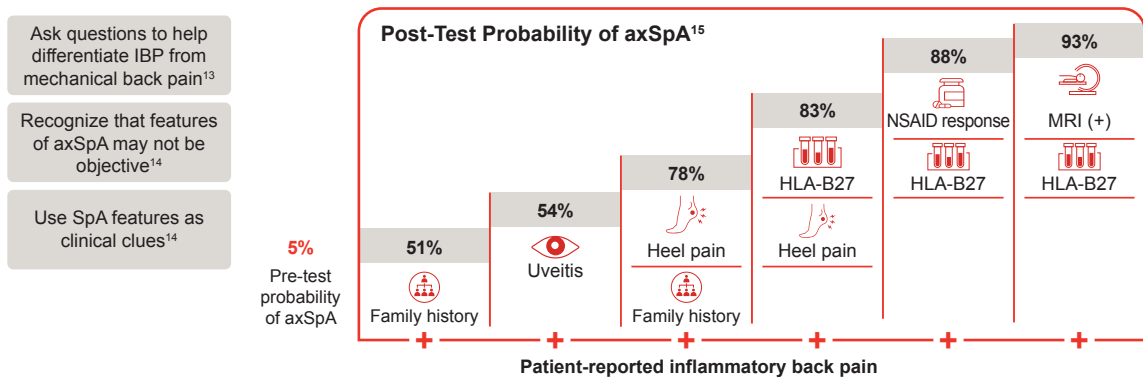
axSpA lacks validated diagnostic criteria.<sup>3</sup> In clinical practice, diagnosis can be based on a range of different assessments and information:<sup>1-3</sup>



## Common clues in axSpA Diagnosis



## Clinical features can help clinicians diagnose axSpA in patients with Inflammatory back pain



axSpA=Axial Spondyloarthritis; CRP=C-Reactive Protein; CVD=Cardiovascular Disease; DISH=Diffuse Idiopathic Skeletal Hyperostosis; ESR=Erythrocyte Sedimentation Rate; HLA=Human Leukocyte Antigen; IBD=Inflammatory Bowel Disease; MRI=Magnetic Resonance Imaging; NSAID=Nonsteroidal Anti-inflammatory Drug; PsA=Psoriatic Arthritis; PsO=Psoriasis; SpA=Spondyloarthritis.

1. Rudwaleit M, et al. *Ann Rheum Dis.* 2009;68:777-763. 2. Ogdie A, et al. *Rheumatol Ther.* 2019;6:255-267. 3. Danve A, et al. *Clin Rheumatol.* 2019;38:625-634. 4. Walsh JA, Magrey M. *J Clin Rheumatol.* 2021;27(8):e547-e560. 5. Voinin-Hertz M, et al. *Semin Arthritis Rheum.* 2020;50(1):48-53. 6. Moltó A, et al. *Best Pract Res Clin Rheumatol.* 2018;32(3):390-400. 7. Strand VC, et al. *J Clin Rheumatol.* 2017;23(7):383-391. 8. Lapane KL, et al. *BMC Fam Pract.* 2021;22(1):251. 9. Zhao SS, et al. *Rheumatology (Oxford).* 2021;60(4):1620-1628. 10. Carvalho PD and Machado PM. *Best Pract Res Clin Rheumatol.* 2019;33(4):1014-27. 11. Winkler AE, Miller M. *Mo Med.* 2022;119(1):79-83. 12. McGonagle D, et al. *Semin Arthritis Rheum.* 2021;51(6):1147-1161. 13. NASS. *Differentiating Inflammatory and Mechanical Back Pain.* April 2018. Available from: <https://nass.co.uk/wp-content/uploads/2020/03/Physiotherapy-modules-1.pdf>. (Accessed May 2024). 14. Deodhar AA. *Am J Managed Care.* 2019;25 (Suppl. 17):S319-S330. 15. Rudwaleit M, et al. *Ann Rheum Dis.* 2004;63(5):535-543.

